



DATE PRESENTING CLINICAL SIGNS

2.26.26 History: Recently diagnosed with hypothyroidism. History of ALKP elevation. Cushing's disease ruled out with low dose dexamethasone suppression testing.

PATIENT

Memphis Hunt

-Current Medications: Levothyroxine 0.6mg tabs, Galliprant 60mg, Gabapentin 300mg caps PRN, Dasuquin.
-Lab work Results: BNP 1590 (0-900), ALKP 384 (23-212).
-Date of Previous IntraPet Ultrasound: No previous.
-Sedation: Trazadone, Torb & Midaz.
-Stat Report: Not requested.
-Imaging Performed by: Andi Parkinson, BS, RDMS.

SPECIES

Canine

BREED

Shepherd Mix

SEX

MN

AGE

6.26.14

WEIGHT

62.6lbs

ELECTROCARDIOGRAPHIC FINDINGS

A six lead ECG is available at both 25 and 50mm/s; 2mm/mV. The average heart rate is 100bpm. The rhythm is sinus in origin, with a p for every QRS complex and vice versa. The P wave morphology is positive with a normal dimension. Normal PR. The QRS morphology is positive with normal dimension. MEA is normal. No ectopic beats, pauses or dysrhythmias observed.
ECG diagnosis: Normal sinus rhythm with respiratory variation.

ECHOCARDIOGRAM FINDINGS

2D, m-mode, color flow and doppler imaging is available. Mild thickening of the mitral valve leaflets with no prolapse into the left atrial lumen. Trace mitral regurgitation with no left atrial dilation. Normal MR velocity. Normal LV diameter with adequate myocardial function. The tricuspid valve appears normal with no significant tricuspid regurgitation. Normal right atrial and ventricular diameter and morphology indicating no overt evidence of pulmonary arterial hypertension. The pulmonic and aortic valves are normal in morphology and mobility. Normal pulmonic and aortic outflow velocities with laminar flow. No obvious aortic and trace pulmonic insufficiency. No pericardial or pleural effusion noted. No obvious cardiac masses.

INTERPRETED BY

Maggie Machen Lamy,
DVM, DACVIM
(Cardiology)

CARDIAC CHART

HOSPITAL NAME

Banfield Towson

REFERRING VET

Dr. Washington

INVOICE

47021

CANINE CARDIAC PARAMETERS	MR VMAX (m/s)	TR VMAX (m/s)	LA/AO (Boon method)	LA/AO (Heart Base; Swe)	FS (%)	EF (%)	EPSS (cm)
NORMAL PARAMETER	4.5-5.5	<2.7	1.3	<1.6	28-40	40-100	<0.6
PATIENT	5.9	NA	NM	1.0	28	54	NM
CANINE CARDIAC PARAMETERS	HR (BPM)	AV VMAX (m/s)	PV MAX (m/s)	BODY WEIGHT (kg)	LA 2D short axis Base view (cm)	LVIDd Avg; 2D and m-mode short axis (cm)	LVIDs Avg; 2D and m-mode short axis (cm)
NORMAL PARAMETER	50-100	0.7-1.7	0.7-1.6	BELOW	BELOW	BELOW	BELOW
PATIENT	140	1.8	1.1	28.4	2.0	3.5	2.6
*Normal chamber parameters expressed as a mean value (SD)				3	1.27 (5.3)	2.46 (2.46)	1.36 (5.5)
BODY WEIGHT DEPENDENT PARAMETERS				5	1.40 (4.5)	2.74 (5.2)	1.60 (4.7)
*Note: All measurements based upon multi-modal images and methods. An average value is reported.				10	1.50 (3.8)	3.27 (3.5)	2.06 (3.1)
				15	1.83 (2.0)	3.71 (2.4)	2.43 (2.1)
				20	2.02 (1.9)	4.14 (2.2)	2.80 (2.0)
				25	2.18 (2.4)	4.48 (2.9)	3.10 (2.5)

Adapted from June Boon, Veterinary Echocardiography, 1998	30	2.33 (3.3)	4.83 (3.9)	3.39 (3.4)
Rishniw M and Hollis NE, J Vet Intern Med 2000; 14:429-435	35	2.48 (4.3)	5.17 (5.0)	3.69 (4.5)
Hansson et al, Vet Rad and Ultrasound 2002	40	2.62 (5.2)	5.48 (6.1)	3.96 (5.4)
Bonagura et al. Echocardiography: principles of interpretation, Vet	50	2.88 (7.1)	6.07 (8.3)	4.46 (7.4)

INTERPRETATION OF THE FINDINGS & FURTHER RECOMMENDATIONS

The cardiac structure and function in this patient is overtly normal. Trace MR may reflect early valve disease and follow up is advised should a murmur develop in the future. No significant valvular regurgitation is noted, and flow through the great vessels is normal. No obvious concurrent issues such as pulmonary hypertension are suspected. The ECG is unremarkable with a normal sinus rhythm.

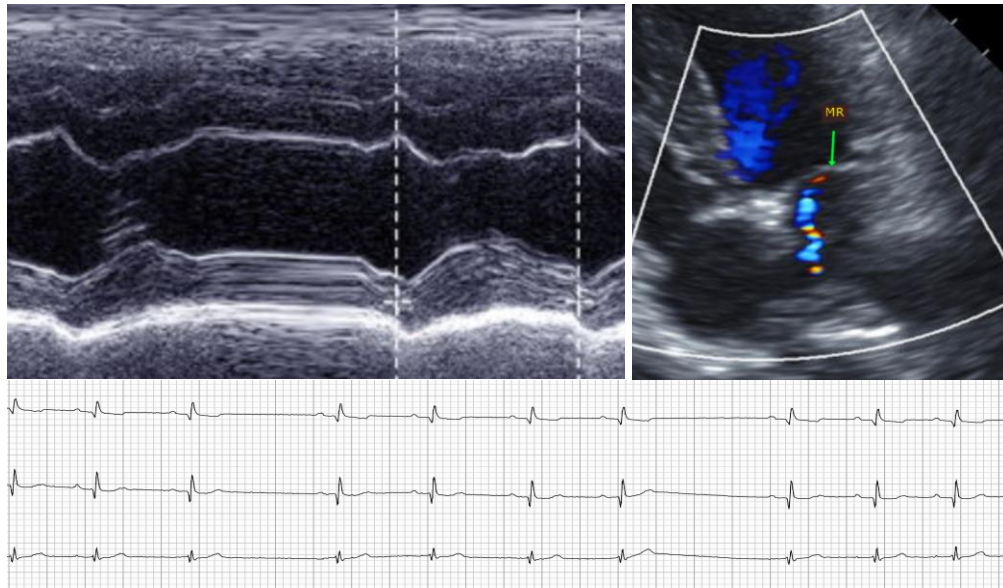
A structural cause for NT-ProBNP elevation is not apparent here, making this potentially a false positive result (a known weakness of the test). Other possible causes for elevated levels of the enzyme should be considered, such as significant arrhythmias, hyperthyroidism, systemic hypertension or renal disease. If no obvious cause is identified, reassessing this patient in 6-12 months is recommended to ensure early disease was not missed.

No cardiac medications are indicated at this time and the prognosis is open. Monitor for development of a cough, labored breathing, exercise intolerance or collapse episodes.

No cardiac contraindication for general anesthesia.

A recheck is recommended in 6-12 months to ensure no progressive issues are identified, sooner should a murmur or any clinical signs of cardiac compromise be noted in the interim.

IMAGES



The information and recommendations provided are based on the images presented by the referring veterinarian. No evaluation can be communicated regarding pathology that was not visible in the image/video clips provided.

Thank you for this referral. This report was generated using transcription software, and minor dictation errors may be present. If the clinical or image interpretation does not parallel your findings or if I can be of any further assistance, please contact me.

Maggie Machen Lamy, DVM
Diplomate of the American College of Veterinary Internal Medicine (Cardiology)
info@sonopath.com